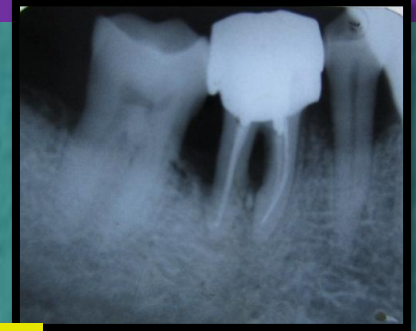
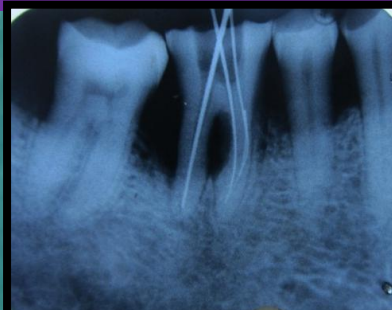
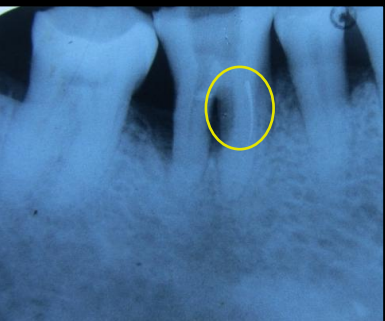
VARIOUS TREATMENT MODALITIES FOR SEPARATED INSTRUMENT

Location of the separated instrument and the shape of the root canal influence prognosis of the treatment. Instrument by pass, Ultrasonics, Messerann kit, instrument retrieval system, surgical retrieval are just few treatment modalities to mention.

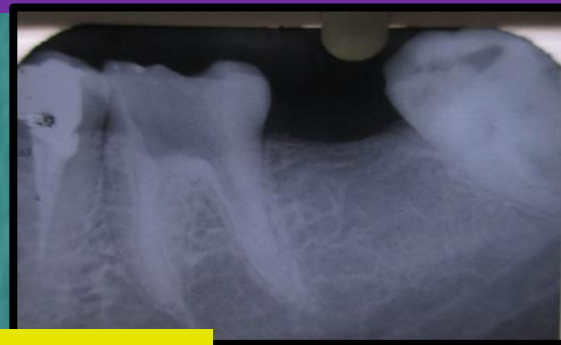
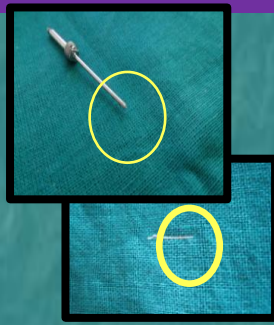
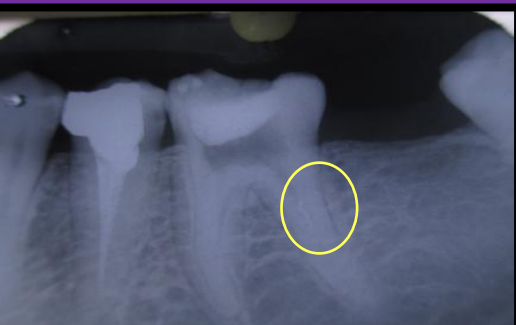
Instrument By Pass

Instrument was successfully by passed in th coronal third of mesiobuccal canal of lower right first molar.



Retrieval with Messerann Technique

Instrument was retrieved successfully with Messerann technique from the middle third of the mesio bucaal canal of lower left first molar.



Surgical Retrieval of Separated Instrument

Instrument was surgically retrieved from apical third of distal root of lower right first molar; apicoectomy and retrograde MTA filling was done.

