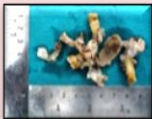
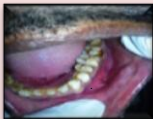

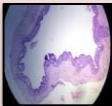
GLANDULAR ODONTOGENIC CYST : A RARE CASE

A 40 year old male patient reported with chief complaint of painful swelling in lower left front tooth region for last 5 months. Extra orally, the swelling was not obvious and did not produce any facial asymmetry.

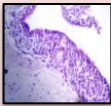
Soft tissue gross specimen showed cystic cavity surrounded by fibrous capsule and was soft in consistency and creamish white in color



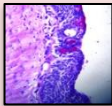
The cystic cavity was lined by a non-keratinised stratified squamous epithelium of variable thickness exhibiting papillary surface. The superficial layer of the epithelial lining consists of cuboidal and in some area columnar cells with cilia. Small microcysts were also seen. PAS positive mucous cells (goblet cells) were seen.



H&E stain(10x)



H&E stain(40x)



PAS stain(40x)

