

HEMISECTION OF GROSSLY CARIOUS LOWER RIGHT FIRST MOLAR

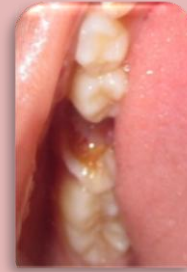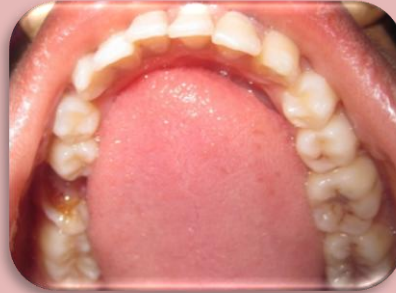NAME : JANAK CHAUHAN

AGE : 15 YEAR SEX:FEMALE

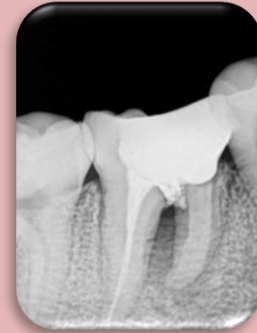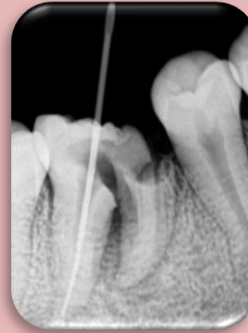
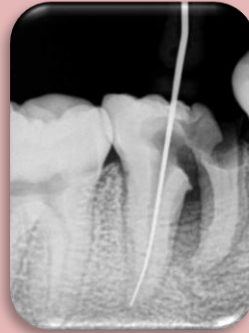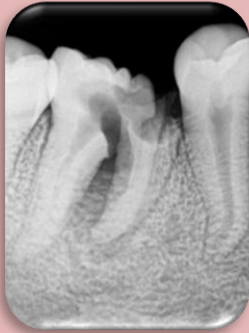
C/O : PAIN IN LOWER RIGHT BACK TOOTH REGION SINCE 15 DAYS

CLINICAL EXAMINATION : GROSSLY CARIOUS 46, CLASS-I CARIES IN 36,37

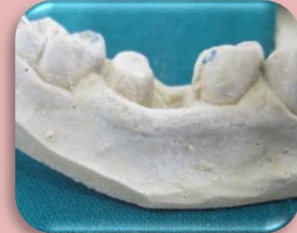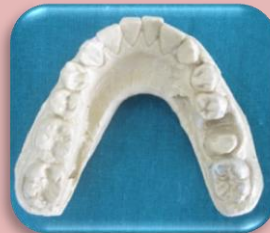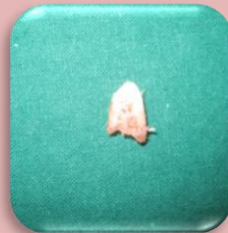PRE-OPERATIVE PHOTOGRAPHS



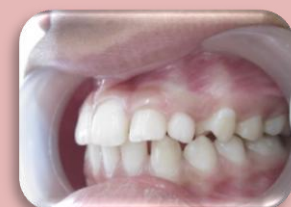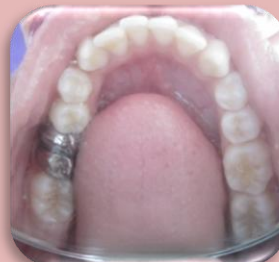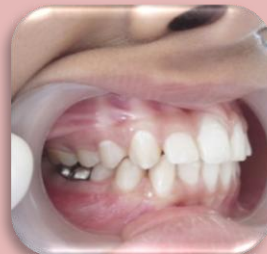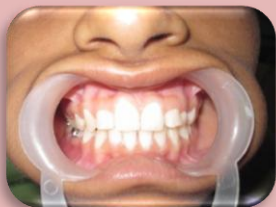DISTAL ROOT RCT IN 46



MESIAL ROOT EXTRACTION & DISTAL CORE BUILD UP



POST-OPERATIVE PHOTOGRAPHS



DEPT OF PEDODONTICS & PREVENTIVE DENTISTRY
GUIDED BY: DR.VIJAY BHASKAR